

ANISAKIDS NEMATODES OF BALTIC COD (*GADUS MORHUA*) AND HERRING (*CLUPEA HERRENGUS*) - DETERMINE A FUTURE OF BALTIC COD?

Mirosław Rozycki¹, Ewa Bilśka – Zając¹, Jacek Karamon¹, Jolanta Zdybel¹, Katarzyna Gradziel Krukowska¹, Ewa Chmurzyńska¹, Agnieszka Pękala-Safińska², Katarzyna Nadolna – Ałtyn³, Magdalena Podolska³, Tomasz Cencek¹

1 - Department of Parasitology and Invasive Diseases, National Veterinary Research Institute, Al. Partyzantów 57, 24 100 Puławy, Poland

2 - Department of Department of Fish Diseases, National Veterinary Research Institute, Al. Partyzantów 57, 24-100 Puławy, Poland

3 - Department of Fisheries Resources, National Marine Fisheries Research Institute. Kollataja 1, 81-332 Gdynia, Poland

Introduction

Anisakiosis is caused by parasites of the *Anisakidae* family. The definitive hosts for *Anisakis* spp. are whales; while pinnipeds serve as final hosts for *Contracaecum osculatum* and *Pseudoerranova* genera. The first intermediate hosts for anisakids are crustaceans. Fish are paratenic hosts. The list of *Anisakidae* paratenic hosts include over 200 fish species. In North Atlantic 75 species of fish are known as parasite hosts. The fish (pelagic and bathypelagic species), including *Gadidae* and *Clupeidae* families (cod and herring). In Baltic Sea cod (*Gadus morhua*) and herring (*Clupea herrengus*) have a great economic importance. Baltic Cod is suffering from high overfishing and the stock currently shows signs of dangerously low biomass level. Cod plays a key role in the Baltic Sea. Both species are heavily infected with anisakid nematodes in the North Atlantic and contiguous seas. Nevertheless up to the last decade anisakids infection in the Baltic Sea was rare. Since 2011 infection levels have increased noticeably. The increase is especially high concerning the infection of cod with the liver worm *Contracaecum osculatum*. The aim of the study was to collect the data on the prevalence of infection with *Anisakidae* in fish from the Baltic Sea.

Materials and Methods

For the study, herring and cod caught in the Baltic Sea were examined. Samples were collected during scientific cruises conducted in April 2016 and January 2017 on the research vessel “Baltica” and from the commercial catches. In total, 296 herring and 1091 cod fish were examined. Fish filets were analyzed for the presence of parasites. On board by candling (white light and UV) and digestion in artificial stomach juice. Species of anisakids were identified by European Union Reference Laboratory (EURLP) protocol “Identification of *Anisakidae* Larvae at the species level by multiplex PCR”.

Results and Discussion: Larvae of *A. simplex* s.s were found in 37 samples of herring (12.5%) and 108 of cod (9.9%). The prevalence and intensity of infection increased with the size of fish and depends on the sampling season (for herring) and the fishing ground. Moreover rarely in cod *P. decipiens* larvae were found 14 (1.2%). Cod liver were found to be highly contaminated with *Contracaecum osculatum*. Larvae were found in 343 (54%) out of 624 examined samples. Number of larvae varied from 1 to 173 with mean 7,7 and median 1.

Cod population is decreasing. This unfavorable phenomenon may be explained by overfishing, presence of death zones, but also by presence of parasites in liver. Cod is a whitefish that accumulates protein reserves in skeletal muscle, while the main energy reserves are stored in the liver, in the form of lipids. In the case of a shortage of food, in the cod first lipids accumulated in the liver are mobilized, then glycogen in the liver and muscle tissue and finally muscle proteins. Larvae of nematodes damage the liver parenchyma, blood vessels and bile ducts of infected fish. Destruction of the liver and further reduction of fat content may reduce the chances of cod surviving periods of limited food availability and, as a consequence, increase the mortality of infected fish. **Conclusion:** In the case of Baltic cod in 2016, negative features of its dynamics were maintained - low fish condition, high 'stocking', low number of older cod in the herd. Presence of the zoonotic parasites in muscle tissue was low compare to other fishing grounds. High prevalence of *Contracaecum osculatum* was observed in cod liver. Destruction of the cod liver may influent mortality of the cod in Baltic.



Fig.1 Baltica research vessel

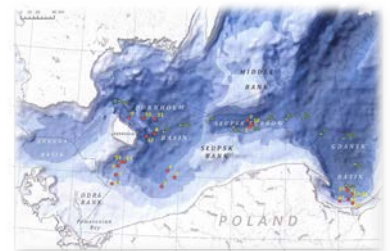


Fig. 2 Map of fishing grounds

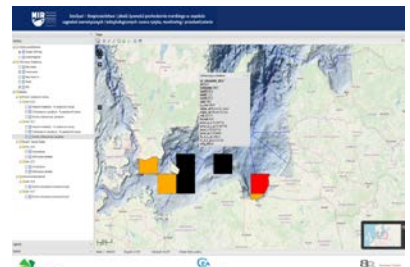


Fig. 3 SeaQual web page

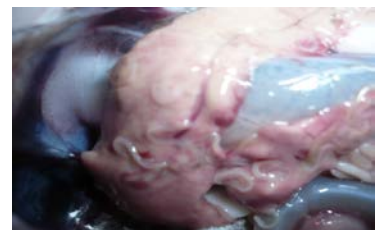

Fig. 4 *Contracaecum osculatum* in Cod liver

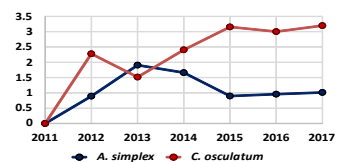


Fig. 5 Prevalence of *C. osculatum* in cod

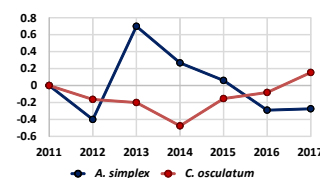


Fig. 6 Incidence of *C. osculatum* in cod

This research was supported by The National Centre for Research and Development under the Strategic Program Biostrateg II (grant no. BIOSTRATEG2/296211/4/NCBR/2016)



NRL Workshop
23-24/05/2019

